

Abstract 177

HENLE'S FIBER LAYER SEGMENTATION WITH DEEP LEARNING ALGORITHMS

Oral

Kesim C.*^[1], Cansiz S.^[2], Guleser U.Y.^[1], Bektas S.N.^[3], Kulali Z.^[3], Gunduz--Demir C.^[2], Hasanreisoglu M.^[1]

^[1]Department of Ophthalmology, Koç University School of Medicine ~ Istanbul ~ Turkey, ^[2]Department of Computer Engineering, Koç University Faculty of Engineering ~ Istanbul ~ Turkey, ^[3]Koç University School of Medicine ~ Istanbul ~ Turkey

Purpose:

Henle's Fiber Layer (HFL) is a retinal layer which can be visualized through its diverse reflectivity pattern that can be acquired by directional optical coherence tomography (D-OCT). In this study we aimed to compare two separate deep learning algorithms that can detect HFL from standard OCT and D-OCT images.

Methods:

Manual HFL segmentation was performed from 20x20 degrees macular D-OCT images of healthy subjects. Two deep neural networks with a UNet architecture (standard-UNet and directional-UNet) were designed and trained to predict current segmentations from standard OCT and D-OCT images. To output a segmentation map, the standard-UNet took only a standard OCT image while the directional-UNet took directional OCT images along with the standard OCT as input. The algorithms were validated on a separate dataset consisted of OCT images of healthy subjects that were not used in training.

Results:

From OCT acquired eyes, 20 were used for training and 23 were used for validation. The trained standard-UNet and directional-UNet algorithms detected HFL with 70.72% and 72.27% sensitivity, 99.69% and 99.69% specificity, and 77.32% and 78.51% f-scores, respectively. Figure 1 shows a sample OCT section with segmentation results. The total HFL volume and mean HFL thickness calculated on validation data were 0.65+/-0.10 mm³ and 23.1+/-3.57 µm for standard-UNet and 0.67+/-0.11 mm³ and 23.6+/-3.80 µm for directional-UNet, respectively. Figure 2 shows sample heat maps created by manual and automated HFL segmentations.

Conclusions:

Automated HFL segmentation can be performed by deep learning algorithms from both standard OCT and D-OCT images.

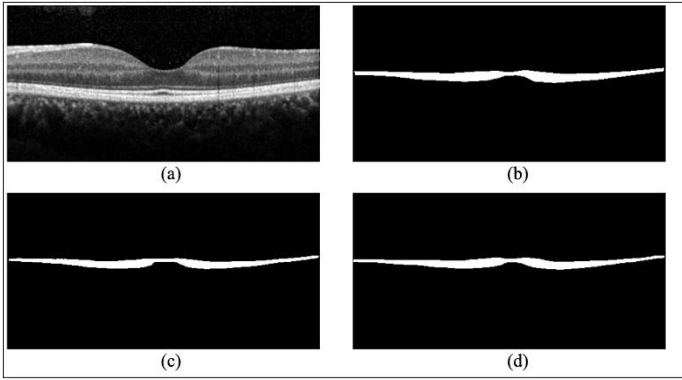


Figure 1 (above): Henle's Fiber Layer (HFL) segmentation of a sample optical coherence tomography (OCT) section. (a) Standard OCT, (b) manual HFL segmentation, (c) automated HFL segmentation performed by the standard-UNet algorithm, (d) automated HFL segmentation performed by the directional-UNet algorithm.

Figure 2 (right): Henle's Fiber Layer (HFL) thickness heat maps calculated from sample optical coherence tomography (OCT) images. Heat maps created from automated segmentations performed by (a) standard-UNet and (b) directional-UNet algorithms are shown. (c) HFL thickness heat map based on manual HFL segmentation.

